



DigiCare® Monograph Series

Beware the Septic Keratosis Obturans: Stealth Public Health Threat

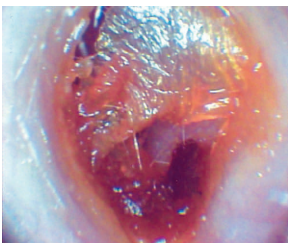
By Max Stanley Chartrand, Ph.D. (Behavioral Medicine)

Once considered rare in the population, **keratosis obturans** are surprisingly common in the population today (see **Fig. 1** on page two). Healthy bodies maintain a cellular pH 7.35-7.45. This aids the outer layer of tissue called keratin to grow outward from the umbo of the ear drum at the rate of about 1mm per day, carrying with it dead skin tissues, debris, bacteria, fungi, and earwax.

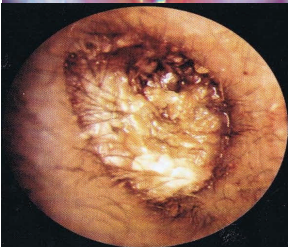
When the cellular pH of the body falls into acidosis (pH 7.1 or below), external ear keratin peels up from the skin below and wraps around itself over and over, until an entire milieu of collected material takes on a life of its own, in many cases becoming dangerously septic (see **Fig. 2** on page 2).

At this point, the effect usually sets off a cascade of **proinflammatory cytokines** (i.e., general inflammation)—often interacting with developing sepsis in the jaw and teeth or other regions, or with implanted prostheses. Over time, this milieu continues to grow until it has formed one, two, three, even four obturans masses (see photos below), before it begins to vascularize into the tissues surrounding it.

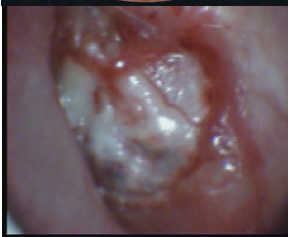We see these especially manifesting in people who are becoming diabetic, or in cases of trauma, ongoing infections, or comprised immunology. Following is a pictorial explanation of what these look like at various stages of development and during removal:



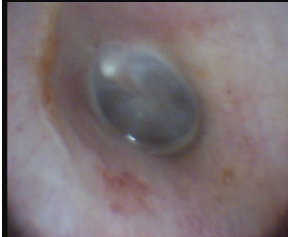Months 3-6—Keratin (outer layer of the external ear canal) begins to peel away from the underlying skin when cellular pH of body falls below pH 7.1 (or pH <6.6 in the EAC)—then, it begins trapping desquamated skin cells, debris, bacteria, fungi, yeasts, pseudomonas, etc., eventually becoming septic, but remaining insulated from one's vascular system. Growing at about 1mm per day, the keratin which normally would grow outward to keep the ear canal clean, instead wraps around itself over and over, trapping more undesirable material into a septic milieu.



Year 4 or 5—Now, it has grown into 3 or 4 keratosis obturans in succession. Unremoved, it potentially can grow into a *External Ear Cholesteatoma* and begins drawing bone fragments from the mastoid bone around it, hollowing out a large cavity out of the EAC. If the mass vascularizes, and septicemia reaches the blood system, lab tests will indicate an acute diverticulosis-like profile with septicemia. Gentle removal is immediately required. (Note: the problem with these in medical practice is that they present as if cerumen accumulations instead of the more dangerous keratosis obturans, because of the veneer of cerumen visible upon otoscopy.)



After Mild Syringing—When the outer debris and earwax veneer are removed with mild syringing with warm antiseptic water, the keratosis covering the obturans becomes plain to see. Instead of being earwax all the way through, revealed instead is a series of keratin membranous accumulations filled with trapped debris and bacteria. In the illustrated case here, there were four of these in succession, which were very difficult to remove. They were already causing severe pro-inflammatory cytokine response and seemed to interact with a similar problem in the patient's teeth and jaw.



After Obturans Removed—A chart on the next page will show the kinds of serious bacteria and fungi found inside many of these accumulations. When it has all been removed, what is left is a (relatively) normal ear canal and tympanic membrane. Often, the physician will prescribe an acetic 4-8% acid or combination cortisone/antibiotic solution to prevent further infection from the obturans. To bring back a healthy layer of keratin over the ear canal, MiraCell® (Pro-Ear®) Botanical Solution can also be used on a daily basis for two weeks continuously and once per week thereafter to maintain it to avoid relapse (see **Fig. 3** on page two).*

Since the introduction of video otoscopy in 1992, public health trends have changed dramatically

- **Chronic disease** in every category has skyrocketed in the general population (Polypharmacy, DMII, Cancer, CVD & Neuropathies).
- As **cellular pH** in the population has dropped in recent years, **fungi, yeasts & pseudomonas**, once rare, are now common.
- Incidence of **absent EAC keratin** has skyrocketed, making **EAC mechanoreceptors** overly sensitive to hearing aids
- **Impacted cerumen** has given way to **keratosis obturans**; untended cases progress to **external ear cholesteatoma**
- **Tympanosclerosis** and other **sclerotic plaques** (due to acidosis) have proliferated approximately 5-fold in the general population

Fig. 1

Potentially Dangerous Microorganisms Common to the Keratosis Obturans

Bacteria/Fungi	Oto Culture	Complications
Acinetobacter Iwoffii	Long developing keratosis obturans	Sepsis; pneumonia; respiratory infections
Enterobacter Cloacae	Untreated injury, infection (pseudomonas)	Sepsis, pneumonia, infection
Pseudomonas aeruginosa/anaerobic	Chronic EO, EM Irritation, pH<6.5	OE, Septicemia, pneumonia, EAC cholesteatoma
S. aureus	Non-sterile earmolds, objects	Internal abscesses, carbuncles, boils
Aspergillus Favus	-pH EM, hypernatremia, DM II (dermatitis response)	Hypersensitive pneumonitis, other systemic disease
Candida Parapsilosis	-pH EM, renal disease, thrush, DMII, gout	Candidiasis, keratosis, Mucosal disease

Fig. 2

DigiCare®

Standard Procedure for Using ProEar Botanical Solution in the Ear...

- Tilt the head sideways to allow you to pour a generous amount of ProEar solution into the ear (enough to cover the ear drum).
- Place wad of tissue at the entrance of the canal and leave there for at least 10–15 minutes
- Carry out the same procedure for opposite ear
- Repeat procedure daily for 2 weeks
- Thereafter, use once per week



Fig. 3

***Disclaimer:** The material in this monograph is strictly educational in nature, and is not intended to diagnose or treat any individual's condition. It is advisable to consult with one's physician on such matters. The author and his associates disclaim any liability in the use of this material.

What sets off a keratosis obturans?

As mentioned earlier, a drop in the body's cellular pH into acidosis state can cause the peeled keratin issue. Today, we have >120 million Americans with pre-diabetes (pH 7.0) and diabetes mellitus type 2 (pH 6.9). The author, in research screenings has found obturans in up to 30-35% of such individuals. It usually correlates with several other conditions, such as acid reflux, hypertension, gout, high triglycerides, IBS, and rheumatoid and osteoarthritis.

More closely aligned to the head and neck region are infections in the teeth and jaw, which are found to co-occur with obturans of the external ear in a subset of individuals. Sepsis of the jaw can interact with sepsis of an advanced obturans. Other causes may be intermittent and transient:

- ◆ A serious bout of acute pneumonia, esp. fungal type, or other serious infection. Ingrown toenail and diverticulosis may also interact.
- ◆ Septic debris developing in or around implanted prostheses, such as artificial joints, shoulders, hips, knees, feet, or implants in the back.
- ◆ Trauma, accident, emotional distress, or toxic exposure. "Cotton Swab Trauma" or imbedment of foreign object have been implicated.
- ◆ Certain medications, especially those that suppress immune system or affect the liver, epithelium, or blood vessel integrity.
- ◆ Toxic effects of tobacco, alcohol, heavy metals, or drug use.

How does one avoid relapse?

Every case is different and are advised to consult with their physician on what may be best for them. However, here are some general guidelines to start the discussion:

- ◆ Change diet & nutrition to conform to the SIRCLE® Program, which helps one raise their cellular pH to pH 7.35-7.45, and addresses unhealed injuries and stressors that contribute negatively to one's health.
- ◆ Have teeth and jaw carefully examined by an oral surgeon who is intimately familiar with problems that cause septicemia conditions.
- ◆ Be examined by an otologist who is particularly knowledgeable in current trends in pseudomonas and keratosis obturans.
- ◆ Ask your physician about setting up a prophylactic antibiotic regimen to assure sepsis does not develop in your implanted prostheses. In cases of chronic inflammation due to prostheses immunology abnormalities, Augmentin 250mg or 500mg taken 3 times per day for two or three days every 3 or 6 months is one approach.
- ◆ Consider using MiraCell as shown in **Fig. 3** to the left.

References for Further Study

- Chartrand, M. S., But What's Wrong with Q-tips®? Archives, *Audiology Online Newsletter*. www.audiologyonline.com, January (2003).
- Chartrand, M. S., Video Otoscopy Observation and Referral: The FDA Red Flags, *The Hearing Professional*, Jan—Feb, 2003, pp. 9—14 (2003).
- Chartrand, M.S. (2010). *Video Otoscopy: A Quantitative View of the Relationship between External Ear Keratin Status and Success in Adaptation to Hearing Aids*. Rye, CO: Digi-Care Behavioral Research. ISBN 978-0-9827756-08.
- Johnson A., and Hawke, M. (1988). Nonauditory physiology of the external ear, *Physiology of the Ear*, eds. A. F., & Santos-Sacchi, J., Raven Press: New York, 41-58.
- Kemp, R. J., and Bankaitis, A. E., Infection control for audiologists, in Hosford-Dunn H., Roeser, R., and Valente, M., eds. *Audiology Diagnosis, Treatment, and Practice Management*, Vol. III, New York: Theime Publishing Group (2000).
- Roland, P. S., Chronic External Otitis, in *Ear, Nose & Throat Journal*, June Supp. (2001).
- Sundstrom, J., and Mulligan, K., *Neuroanatomy Interactive Syllabus*, Ch. 7: Auditory System, University of Washington (2002).

Contact: DigiCare® Behavioral Research, 820W. Cottonwood Lane, Suite #6, Casa Grande, AZ 85122—(520)509-6380